

Optic Disk Segmentation Using Histogram Analysis

Bambang Krismono Triwijoyo
Universitas Bumigora, Mataram, Indonesia

Article Info

Article history:

Received February 24, 2022

Revised February 26, 2022

Accepted March 01, 2022

Keywords:

Optic Disk
Segmentation
Histogram Analysis

ABSTRACT

In the field of disease diagnosis with ophthalmic aids, automatic segmentation of the retinal optic disc is required. The main challenge in OD segmentation is to determine the exact location of the OD and remove noise in the retinal image. This paper proposes a method for automatic optical disc segmentation on color retinal fundus images using histogram analysis. Based on the properties of the optical disk, where the optical disk tends to occupy a high intensity. This method has been applied to the Digital Retinal Database for Vessel Extraction (DRIVE) and MESSIDOR database. The experimental results show that the proposed automatic optical segmentation method has an accuracy of 55% for DRIVE dataset and 89% for MESSIDOR database.

Copyright ©2022 The Authors.

This is an open access article under the [CC BY-SA](https://creativecommons.org/licenses/by-sa/4.0/) license.



Corresponding Author:

Bambang Krismono Triwijoyo,
Universitas Bumigora, Mataram, Indonesia.
Email: bkrismono@universitasbumigora.ac.id

How to Cite: B. K. Triwijoyo, "Optic Disk Segmentation Using Histogram Analysis," *International Journal of Engineering and Computer Science Applications (IJECSA)*, vol. 1, no. 1, pp. 27-34, Mar. 2022. doi: [10.30812/ijecsa.v1i1.1799](https://doi.org/10.30812/ijecsa.v1i1.1799).

1. INTRODUCTION

In modern ophthalmology, eye diseases are diagnosed using computer-aided software. And optical disc (OD) detection is a very important step for retinal image analysis in diagnosis. The OD is one of the main features for extracting the anatomical structures of the retina as illustrated in Figure 1. The optic disc can be defined as the lighter circular area in the retinal fundus image where the blood vessels converge and the optic nerve is formed. OD detection is required for diagnosis using computer aids of various eye diseases such as glaucoma and diabetic retinopathy, where the main difficulty of OD segmentation is to pinpoint the exact location of OD and eliminate noise in retinal images [1]. Figure 1 shows the fundus image with the Center of OD on the grayscale image and the Region of Interest (ROI) of the color image. The purpose of this study is to implement a method for automatic optical disc segmentation on color retinal fundus images without using histogram analysis. Based on the properties of optical disks, where optical disks tend to occupy high intensity.

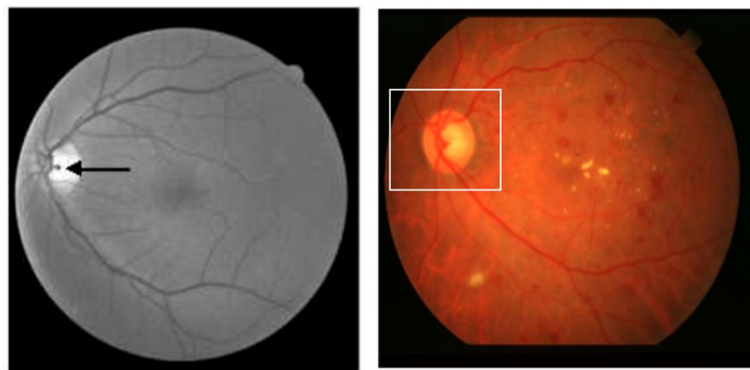


Figure 1. Detected Center of OD (left), Region of Interest Detected (right)

Many optical disk segmentation and detection methods have been proposed previously. In [1], The method of Automatic Optic Disc Detection From Retinal Images by a Line Operator is proposed. In this method, the line operator is designed to capture such circular brightness structure, which evaluates the image structures among the OD, macula, and retinal blood vessels. In [2], Automatic optical disk detection in retinal images method using hybrid vessel phase portrait analysis has been proposed. Numerical experiments on OD localization showed that the proposed approach yielded the highest results: 100% accuracy for normal quality and 97.38% for poor quality images.

Furthermore, the method of automatic detection of the optic disc in color fundus retinal images using a circle operator has been proposed by [3]. But in this method, the balance between detection accuracy and processing time. In this work, all pixels excluding the 0-10 pixel intensity are considered to reduce the OD detection. From [4] proposed an algorithm for OD detection based on structured learning. The performance of the proposed method tends to stagnate when the number of patches used to train the forest is greater than 106. In [5] proposed an OD detection method using a similarity model based on the presented clustering to simulate the human screening mechanism for the visual system for fundal image detection. The experimental results show that the detection accuracy reaches 94%. In addition, an active fitting and contour ellipse is adopted after the convex hull detection to achieve OD segmentation. Meanwhile, in [6] Propose a vessel clustering technique endowed with a new correction and vessel transformation (VT) procedure that measures the distance to the main cluster. The algorithm is integrated into the space-scale analysis (SS) to detect the edge of the OD.

While in [7] proposed an automated system for localization and detection of optical discs. This method localizes the optical disc using averaging and thresholding filters to extract the region of interest (ROI) containing the optical disc to save time and detect the optical disc boundary using the Hough transform. achieved an average accuracy of 96.7% for localization and an average area under the receiver operating characteristic curve of 0.958 for optical detection. On [8] also proposed detection of anatomical structures of the fovea and optic disc on color fundus radiographs of patients with visible lesions. The detection algorithm consists of five steps: selection of the area in the image where the optical disc is located using the Sobel operator, optical disc boundary extraction applying the Hough transform to detect the center and diameter of the optical disc, detection of the ROI (desired region) where the fovea is located based on the center of the optical disc and diameter, fovea detection in ROI.

Furthermore, an OD localization method and a segmentation algorithm were developed by [9]. First, candidate OD locations were identified using template matching. The templates are designed to adapt to different image resolutions. Then, the characteristics of the vessel on the OD are used to determine the location of the OD. Initialized by the detected OD center and estimated OD

radius, a fast hybrid level-set model, combining regional and local gradient information, is applied to disk boundary segmentation. The morphological screening was used to remove blood vessels and bright areas other than OD that affected segmentation in the peripapillary area. In [10] presents an automated OD parameterization technique based on segmented OD and cup regions obtained from retinal images. The proposed OD segmentation method integrates localized image information around each point of interest in multi-dimensional feature space to provide resistance to variations found within and around the OD region.

The latest [11] Proposes a method for localization and isolation of the optic disc and the discovery of exudate on retinal images. A new algorithm was introduced to localize and group the optic disc before the secretion process because it appears in the same color, density, and contrast as other features of the retinal image. The algorithm used uses three steps to extract exudate from physiological properties. In fundus images, the first step depends on the intensity threshold, the second is based on morphological processing and the third step strategically combines steps 1 and step 2 to reveal all exudates thereby eliminating any kind of false positives. While in [12] proposed an automated algorithm based on digital curve transformation (DCUT) to detect OD and exudates in low contrast images. The proposed algorithm consists of three main stages. Initially, bright lesion candidates in the image were extracted using DCUT and modified curvature coefficient of the enhanced retinal image. Furthermore, the detection of new OD and boundary extraction methods based on DCUT and level set methods were carried out. Finally, a bright lesion map (BLM) image was generated, and to differentiate between exudate and OD (i.e. false detection for late exudate detection), candidate pixels extracted in BLM that were not in the OD region (detected in the previous step) were considered as bright lesions that were detected in the previous step. actually. Finally in [13] Propose an OD localization framework, starting with the process of eliminating pixels below the average brightness level of the retinal image. Next, a modified strong ranking order-based method was used for edge detection. Finally, a circular Hough transform (CHT) was performed on the retinal images obtained for regional localization of OD.

From many related works, using various methods of segmentation and OD detection and tested on various datasets with varying results. In contrast to previous related work, this study uses a different segmentation method, namely a method for automatic optical disc segmentation on colored retinal fundus images without using histogram analysis. Based on the properties of optical disks, where optical disks tend to occupy high intensity. The method proposed in this study was tested using the Digital Retinal Database for Vessel Extraction (DRIVE) dataset and MESSIDOR database. The remaining sections are presented as follows. The second part will describe the materials and methods, while the results and discussion will be presented in the third part of this paper. Finally, the work is concluded in the fourth part.

2. RESEARCH METHOD

Input data in the form of color retinal images with the RGB format (Red, Green, Blue) form a 3-dimensional structure of $256 \times 256 \times 3$ pixels. The RGB format was chosen because it retains original image information and in the absence of compression methods, making it easy to process. The image size of $256 \times 256 \times 3$ pixels was chosen to reduce the complexity of the original image size. This input data format was obtained through the image resizing process using bicubic interpolation [14, 15]. This method is selected because the result is finer at the edges than the bilinear interpolation. Bicubic is an ideal combination of process time and quality output.

ROI detection begins by determining the area of the Optic Disk (OD) using the [16] method by extracting the green retinal image channel which gives the highest contrast between OD and background and has a better OD texture. Since OD tends to be a circle, the OD diameter is calculated in pixels using the broad circle formula πr^2 , to calculate the OD region (where r is the radius of the circle). Furthermore, due to the brightest intensity of the OD, histogram analysis was performed to determine the intensity value of the OD region, to determine the number of pixels from the highest intensity level, and to compare it to $1.5 \times$ the area of OD. If $\leq 1.5 \times$ the area of OD, then the number of pixels added from the intensity of the pixel level is below the next highest intensity level. The total number of pixels continuously added over the total value of $\leq (1.5 \times \text{OD area})$. Figure 2 shows the histogram of the retinal image in grayscale format.

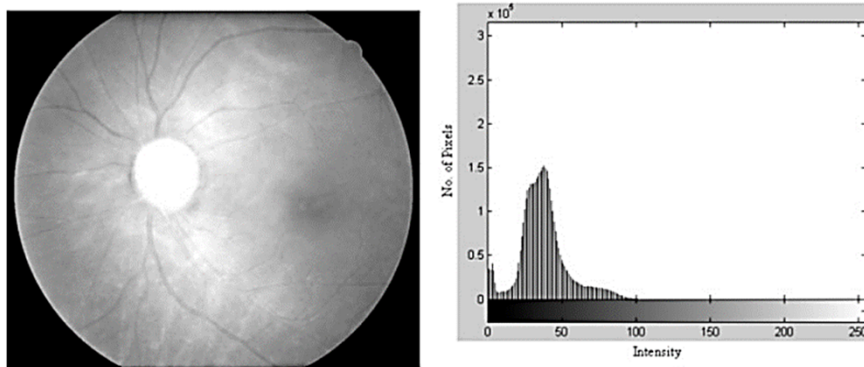


Figure 2. Histogram Green Channel of Retina Image

After the total value of $\geq (1.5 \times \text{OD area})$, we select this intensity level as the threshold intensity value for the segmentation of the potential area of OD. If $f(x, y)$ is the image and T is the threshold value, then the output image $g(x, y)$ is obtained based on the following Equation 1.

$$g(x, y) = \begin{cases} 1 & \text{if } f(x, y) \geq T \\ 0 & \text{otherwise} \end{cases} \quad (1)$$

Figure 3 shows the input image and the results of the potential OD segmentation.

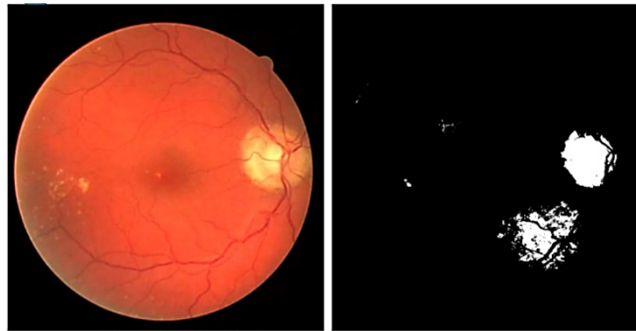

Figure 3. Original Image (left), Thresholded Potential Optic Disk (right)

Determining the potential area of OD by calculating the number of pixels in each area, which has a pixel count of about 50% to 150% of the OD area, using region growing until each area is labeled. Each potential region of OD calculated the center point of the OD, from the average of its x-y point coordinates. The selection of the OD using the Hough transform is based on Equation 2.

$$\begin{aligned} x_i &= a + R \cos(\theta) \\ y_i &= b + R \sin(\theta) \end{aligned} \quad (2)$$

Where (x_i, y_i) is the candidate of the edge points of the OD area, $r = R$ the radius of the OD region, and (a, b) is the center-point coordinates obtained from the image gradient. $f(x, y)$ at the location (x, y) based on Equation 3.

$$G[f(x, y)] = [G_x, G_y] = \left[\frac{\partial f}{\partial x}, \frac{\partial f}{\partial y} \right] \quad (3)$$

This process is repeated for each edge point of the potential OD area. Figure 4 shows the results of OD segmentation.

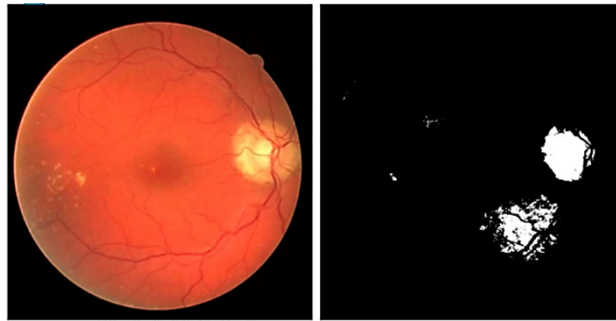


Figure 4. Original Image (left), Optic Disk Detected (right)

Here is the Algorithm of Detection of the Optic Disk (OD) area:

Algorithm 3.2. Detection of Optic Disk (OD) Area

Input: Resized Image

Output: Image with detected OD area

```

1 : Read the green channel of the input image
2 : Calculate the average of 1.5 x area of OD ( $L = 1.5 \times (\pi r^2)$ ) let  $r = 60$ 
3 : Do histogram analysis for threshold values
4 :   Number of Pixel ( $t$ ) = 0
5 :   Read the highest intensity value of image pixels ( $i$ )
6 :   While  $t \leq L$ 
7 :     Read the number of pixel intensity  $i$  ( $pi$ )
8 :      $t = t + pi$ 
9 :      $i = i - 1$ 
10 :   End
11 :   Read value  $i$  as a threshold value ( $T$ )
12 :   Do image segmentation using a threshold value  $T$  using Equation 1.
      
$$g(x, y) = \begin{cases} 1 & \text{if } f(x, y) \geq T \\ 0 & \text{otherwise} \end{cases}$$

12 :   For  $i = 1$  to the number of areas the histogram segmentation results
13 :     Number of pixels ( $t$ ) = 0
14 :     Determine initial coordinate points within the area by random
15 :   End
16 :   While  $t \leq L$ 
17 :      $t = t + pi$ 
18 :     Do region growing on 8 neighboring pixels
19 :   End
20 :   For  $j = 1$  to the number of areas the segmentation results of the growing region
21 :     Determine the center point of the area from the average of its x-y coordinates
22 :     Circle shape detection using Hough transform
23 :     For  $k = 1$  to number of the edge pixel area
24 :       Calculate coordinates  $(x_i, y_i)$  using Equation 2.
      
$$\begin{aligned} x_i &= a + R \cos(\theta) \\ y_i &= b + R \sin(\theta) \end{aligned}$$

25 :       Calculate the image gradient using Equation 3.
      
$$G[f(x, y)] = [G_x, G_y] = \left[ \frac{\partial f}{\partial x}, \frac{\partial f}{\partial y} \right]$$

26 :     End
27 :   End
28 : End
29 : Select the area closest to the shape of the circle as the OD area

```

3. RESULT AND ANALYSIS

The OD segmentation process begins with the detection of the optic disk location, then proceeds with the determination of the Region of interest (ROI) in the area around the optic disk and then cropping the image on ROI. The following sub-sections explain

the results of the implementation of OD Segmentation. Optic disk detection is needed to determine the region of interest, the optic disk is the brightest area in the retina, determining the location of the optical disk center based on the intensity of the image area. Figure 5 shows the results of optical disk detection, where the results of detecting the center point of the optic disk (OD) area from an input image sample marked with a black cross.

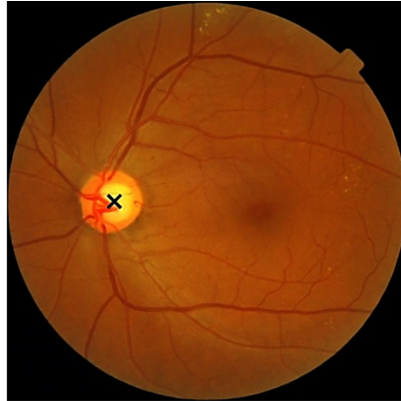


Figure 5. The Result of OD Detection, Where the (x) Sign is the Center of the OD

This research used the DRIVE dataset to test and validate the results of the implementation of optical disk detection, DRIVE, or Digital Retinal Images for Vessel Extraction has been established to enable comparative studies on segmentation of blood vessels in retinal images. Each image has been JPEG compressed and was captured using 8 bits per color plane at 768 by 584 pixels. The set of 40 images is divided into training, and a test set, both containing 20 images. In this experiment, 20 images were taken from the test set. Figure 6 shows the results of implementing the OD detection algorithm.

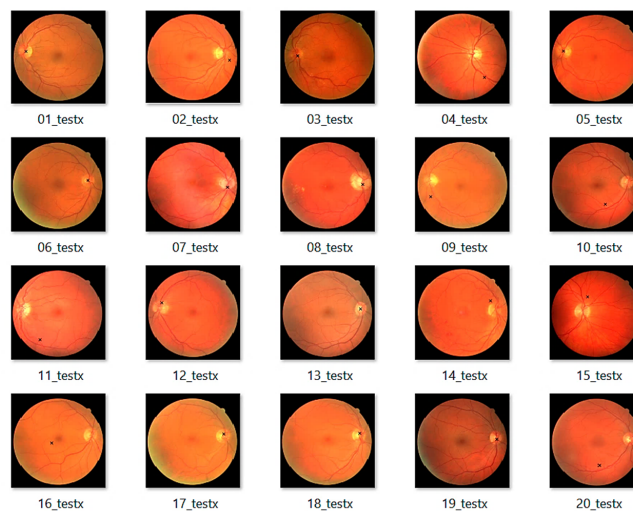


Figure 6. The Result of OD Detection on DRIVE Database

In Figure 6, there is a small black (x) sign that is the center of OD. From 20 test images, 11 images detected OD correctly, and nine images failed. The results of the detection of OD in the database DRIVE are not good because the success rate is still 55%. In the trial model MESSIDOR database will be used, which contains 1200 images. The process of determining the region of interest area is carried out based on the central point of the OD area and then cropping to a specific size, in this study the size of 256 x 256 pixels region of interest (ROI) is used. The implementation of the algorithm for determining the region of interest is based on the OD area center determination algorithm, so it must first load the OD detection algorithm first and then continue the process of determining the ROI area. Figure 7 shows the results of the process of implementing the region of interest algorithm on the first 100 images of the

MESSIDOR database. Determination of sample size refers to [17] which states that the larger the existing population sample size the better, but there is a minimum limit that must be taken by researchers in statistical data analysis. 30 samples, then in this study the number of samples chosen was 100 of 1200 images of retinal images from the Messidor database.

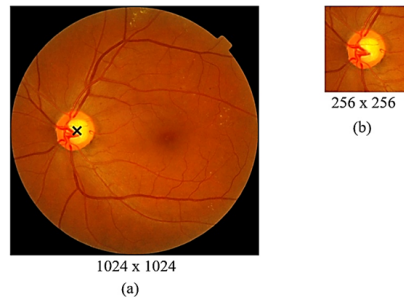


Figure 7. (a) Image Results of OD Detection, (b) Cropping Results in ROI Area

From 100 samples image, 89 or 89% of images correctly detected the location of OD and precisely determined the area of ROI, while ten images failed to determine the location of OD and identified the area of ROI, this is because there is an area in the retina whose brightness level exceeds the average brightness level of OD. Figure 8. shows an image that failed for OD detection and determination of the ROI area.

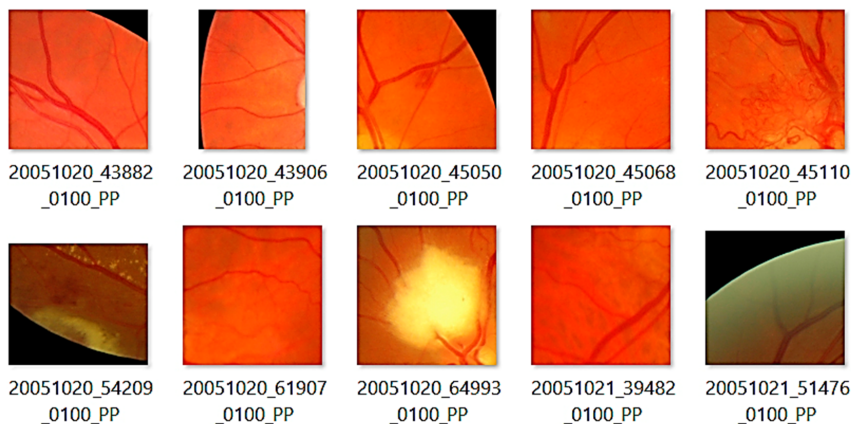

Figure 8. Image Results that Fail OD Detection and Determine the ROI Area

4. CONCLUSION

This paper applies an algorithm for automatic optical disc segmentation on color retinal fundus images using histogram analysis. This method has been applied to the Digital Retinal Database for Vessel Extraction (DRIVE) and the MESSIDOR database. The experimental results show that the proposed automatic optical segmentation method has an accuracy of 55% for the DRIVE dataset and 89% for the MESSIDOR database. Although this result is not better than the previous related work, it has potential for further development. Our future work is to combine the proposed method with hybrid vessel phase portrait analysis to get better accuracy results.

5. DECLARATIONS

AUTHOR CONTRIBUTION

Author contributed to the writing of this article.

FUNDING STATEMENT

-

COMPETING INTEREST

The author declares no conflict of interest in this article.

REFERENCES

- [1] S. Lu and J. H. Lim, "Automatic optic disc detection from retinal images by a line operator," *IEEE TRANSACTIONS ON BIOMEDICAL ENGINEERING*, vol. 53, no. 7, pp. 1–6, 2010.
- [2] N. Muangnak, P. Aimmanee, and S. Makhanov, "Automatic optic disc detection in retinal images using hybrid vessel phase portrait analysis," *Medical and Biological Engineering and Computing*, vol. 56, no. 4, pp. 583–598, 2018.
- [3] M. N. Reza, "Automatic detection of optic disc in color fundus retinal images using circle operator," *Biomedical Signal Processing and Control*, vol. 45, pp. 274–283, 2018.
- [4] Z. Fan, Y. Rong, X. Cai, J. Lu, W. Li, H. Lin, and X. Chen, "Optic Disk Detection in Fundus Image Based on Structured Learning," *IEEE Journal of Biomedical and Health Informatics*, vol. 22, no. 1, pp. 224–234, 2018.
- [5] L. Y. Xue, J. W. Lin, X. R. Cao, S. H. Zheng, and L. Yu, "Optic disk detection and segmentation for retinal images using saliency model based on clustering," *Journal of Computers (Taiwan)*, vol. 29, no. 5, pp. 66–79, 2018.
- [6] A. Budai, A. Aichert, B. Vymazal, J. Hornegger, and G. Michelson, "Optic disk localization using fast radial symmetry transform," *Proceedings - IEEE Symposium on Computer-Based Medical Systems*, pp. 59–64, 2013.
- [7] M. Usman Akram, A. Khan, K. Iqbal, and W. H. Butt, "Retinal images: Optic disk localization and detection," *Lecture Notes in Computer Science (including subseries Lecture Notes in Artificial Intelligence and Lecture Notes in Bioinformatics)*, vol. 6112 LNCS, no. PART 2, pp. 40–49, 2010.
- [8] J. Pinão and C. M. Oliveira, "Fovea and optic disc detection in retinal images with visible lesions," *IFIP Advances in Information and Communication Technology*, vol. 372 AICT, pp. 543–552, 2012.
- [9] H. Yu, E. S. Barriga, C. Agurto, S. Echegaray, M. S. Pattichis, W. Bauman, and P. Soliz, "Fast localization and segmentation of optic disk in retinal images using directional matched filtering and level sets," *IEEE Transactions on Information Technology in Biomedicine*, vol. 16, no. 4, pp. 644–657, 2012.
- [10] G. D. Joshi, J. Sivaswamy, and S. R. Krishnadas, "Optic disk and cup segmentation from monocular color retinal images for glaucoma assessment," *IEEE Transactions on Medical Imaging*, vol. 30, no. 6, pp. 1192–1205, 2011.
- [11] A. H. Al-Sharfaa, A. Y. Yousif, and E. H. Al-Saadi, "Localization of Optic Disk and Exudates Detection in Retinal Fundus Images," *Journal of Physics: Conference Series*, vol. 1804, no. 1, 2021.
- [12] M. Esmaeili, H. Rabbani, A. M. Dehnavi, and A. Dehghani, "Automatic detection of exudates and optic disk in retinal images using curvelet transform," *IET Image Processing*, vol. 6, no. 7, pp. 1005–1013, 2012.
- [13] H. M. Ünver, Y. Kökver, E. Duman, and O. A. Erdem, "Statistical edge detection and circular hough transform for Optic disk localization," *Applied Sciences (Switzerland)*, vol. 9, no. 2, pp. 1–16, 2019.
- [14] J. Titus and S. Geroge, "A Comparison Study On Different Interpolation Methods Based On Satellite Images," *International Journal of Engineering Research & Technology*, vol. 2, no. 6, pp. 82–85, 2013.
- [15] S. Yuan, M. Abe, A. Taguchi, and M. Kawamata, "High accuracy bicubic interpolation using image local features," *IEICE Transactions on Fundamentals of Electronics, Communications and Computer Sciences*, vol. E90-A, no. 8, pp. 1611–1615, 2007.
- [16] A. Bhuiyan, R. Kawasaki, T. Wong, and R. Kotagiri, "A New and Efficient Method for Automatic Optic Disc Detection Using Geometrical Features," in *World Congress on Medical Physics and Biomedical Engineering*, vol. 25, no. 4, 2009, pp. 2295–2298.
- [17] J. Cohen, "Approximate power and sample size determination for common one-sample and two-sample hypothesis tests," *Educational And Psychological Measurement*, vol. 30, no. 4, pp. 811–831, 1970.